

Original Research Article

A STUDY OF HISTOPATHOLOGICAL SPECTRUM OF SYNOVECTOMY AND SYNOVIAL BIOPSIES.

Pasam Ramana Kumari¹, Madhavi Kolakonda², Vijayasree Mandava³, Roopa dixith Nagasaram⁴

¹Associate Professor, Department of Pathology, Guntur Medical College, Guntur, Andhra Pradesh, India.

²Assistant Professor, Department of Pathology, Guntur Medical College, Guntur, Andhra Pradesh, India.

³Professor and HOD, Department of Pathology, Siddhartha Medical College, Vijayawada, Andhra Pradesh, India.

⁴Assistant Professor, Department of Pathology, Siddhartha Medical College, Vijayawada, Andhra Pradesh, India.

Received : 29/04/2024
Received in revised form : 22/06/2024
Accepted : 07/07/2024

Corresponding Author:

Dr. Roopa Dixith Nagasaram,
Assistant Professor, Department of
Pathology, Siddhartha Medical
College, Vijayawada, Andhra Pradesh,
India.
Email: drnrnixith@gmail.com

DOI: 10.5530/ijmedph.2024.3.3

Source of Support: Nil,
Conflict of Interest: None declared

Int J Med Pub Health
2024; 14 (3); 11-15

ABSTRACT

Background: The synovium, a soft tissue lining diarthrodial joints, tendon sheaths, and bursae, plays a pivotal role in various arthritides. This study aims to evaluate the histopathological spectrum of synovectomy and synovial biopsies, assessing their diagnostic value in neoplastic, granulomatous diseases, and infections.

Materials and Methods: This cross-sectional descriptive study was conducted in the Department of Pathology at Siddhartha Medical College, Vijayawada, from January 2021 to January 2023. A total of 100 synovectomies and synovial biopsies, obtained via open or arthroscopic methods, were included. Samples were fixed in 10% buffered formalin, processed, and stained using hematoxylin and eosin and special stains as necessary. Clinical, demographic, histopathological, radiological, and serological data were reviewed.

Results: The study revealed a higher prevalence of synovial lesions in individuals aged 51-70 years (38%) and 71-90 years (32%), with females predominantly affected (60%). Inflammatory joint diseases comprised 40% of cases, with chronic nonspecific synovitis (18%) being the most common. Septic arthritis (10%), tuberculous synovitis (6%), and rheumatoid arthritis (6%) were also notable. Degenerative joint diseases accounted for 22% of cases, including osteoarthritis (10%), gout (3%), pseudogout (3%), ochronosis (2%), and avascular necrosis (5%). Tumor and tumor-like lesions constituted 37% of cases, with giant cell tumor of the tendon sheath (15%) and synovial chondromatosis (8%) being prominent.

Conclusion: The study emphasizes the diagnostic value of histopathological examination in early and ambiguous cases of synovial pathology. The prevalence of inflammatory, degenerative, and tumor-like conditions reflects the necessity for comprehensive evaluation in managing joint diseases.

Keywords: Synovium, histopathology, synovectomy, synovial biopsy, arthritis, inflammatory joint disease.

INTRODUCTION

The synovium, a specialized connective tissue lining the inner surface of diarthrodial joints, tendon sheaths, and bursae, comprises an intimal layer of type A (macrophages) and type B (fibroblasts) synoviocytes and a subintimal layer of connective tissue.^[1,2] With the increasing prevalence of conditions such as obesity and sedentary lifestyles, along with the rising life expectancy, arthritis has emerged as a significant cause of morbidity across

various demographics.^[3,4] Notably, the synovium is the primary site of pathological changes in most inflammatory arthritides, and its detailed examination can offer profound insights into the underlying pathogenetic mechanisms, thereby informing targeted treatment strategies.^[5]

Histopathological examination of synovial biopsies provides critical etiological information, especially in the early stages of joint diseases when there is monoarticular involvement.⁶ This diagnostic approach is crucial for identifying specific

inflammatory, degenerative, and neoplastic conditions that affect the synovium, enabling timely and appropriate therapeutic interventions.

This study aims to delineate the histopathological spectrum of synovectomy and synovial biopsies received in our pathology department. By systematically analyzing these samples, we seek to assess the diagnostic value of synovial biopsies in the evaluation of various arthritides, including neoplastic, granulomatous diseases, and infections.

Aim & Objectives

To study the histopathological spectrum of synovectomy and synovial biopsies in various arthritides.

To assess the diagnostic value of synovial biopsies in evaluating neoplastic, granulomatous diseases, and infections.

MATERIAL AND METHODS

Study Design: This study is a cross-sectional descriptive analysis of synovial biopsies and synovectomies received in the Department of Pathology at Siddhartha Medical College, Vijayawada, over a period of two years from January 2021 to January 2023.

Inclusion and Exclusion Criteria

- Inclusion Criteria: All synovial biopsies and synovectomies received in the Department of Pathology, Siddhartha Medical College, during the study period, provided they had adequate material and sufficient clinical details.
- Exclusion Criteria: Samples with inadequate material or insufficient clinical details were excluded from the study.

Sample Collection: A total of 100 synovectomies and synovial biopsies were included in the study. These samples were obtained through either open or arthroscopic methods. Cases with inadequate material or insufficient clinical details were excluded from the study.

Processing of Samples: Biopsies were fixed in 10% buffered formalin immediately after collection. The fixed tissues were then processed routinely using an automated tissue processor. Sections of 4 to 5 microns thickness were cut using a Leica manual rotary microtome.

Staining Techniques: All sections were stained with hematoxylin and eosin (H&E) to evaluate general histopathological features. Special stains, such as acid-fast stain, were employed when necessary to identify specific pathogens or pathological conditions.

Data Collection: Clinical details, including demographic data, histopathological features, radiological findings, and serological data, were retrieved from the patients' medical records. These details were meticulously reviewed and recorded.

Data Analysis: The histopathological features of each sample were categorized into inflammatory, degenerative, and tumor/tumor-like lesions. The

data were analyzed to determine the prevalence of various synovial pathologies across different age groups and genders. Statistical analysis was performed using descriptive statistics to summarize the findings.

Quality Control: To ensure accuracy and consistency, all histopathological examinations were conducted by experienced pathologists. Regular quality control checks were implemented throughout the processing and analysis phases.

Statistical Methods: Descriptive statistics, including mean, median, and percentages, were used to summarize the data. The prevalence of different synovial pathologies was calculated and compared across age groups and genders. Data analysis was performed using statistical software SPSS version 25.0.

Ethical Considerations: The study protocol was reviewed and approved by the Institutional Ethics Committee of Siddhartha Medical College. Informed consent was obtained from all patients prior to the collection of synovial biopsies.

RESULTS

A total of 100 samples of synovectomy and synovial biopsies were examined. The age distribution showed a higher prevalence of cases in the 51-70 years category (38%) and the 71-90 years category (32%). [Table 1]

In terms of gender, females were predominantly affected (60%), with a male-to-female ratio of 1:1.5. [Table 2]

Inflammatory Joint Diseases

- Septic arthritis was identified in 10 cases, with a higher incidence among females (6) compared to males (4).
- Tuberculous synovitis was observed in 6 cases, with 4 occurring in males and 2 in females.
- Rheumatoid arthritis (RA) was detected in 6 cases, predominantly in females (5) compared to males (1).
- Chronic nonspecific synovitis accounted for 18 cases, predominantly affecting females (14) compared to males (4).

Degenerative Joint Diseases:

- Osteoarthritis (OA) was observed in 10 cases, with 6 occurring in females and 4 in males.
- Gout was seen in 3 cases, affecting 2 males and 1 female.
- Pseudogout was present in 3 cases, with 2 females and 1 male affected.
- Ochronosis was exclusively noted in 2 males.
- Avascular necrosis was identified in 5 cases, with 3 in males and 2 in females.

Tumor and Tumor-like Lesions

- Synovial chondromatosis was found in 8 cases, affecting 6 females and 2 males.
- Giant Cell Tumor (GCT) of tendon sheath was observed in 15 cases, with 8 males and 7 females affected.

- Pigmented Villonodular Synovitis (PVNS) was identified in 4 cases, equally distributed between males and females.

Synovial lipoma arborescence was found in 10 cases, predominantly affecting females (7) compared to males (3). [Table 2]

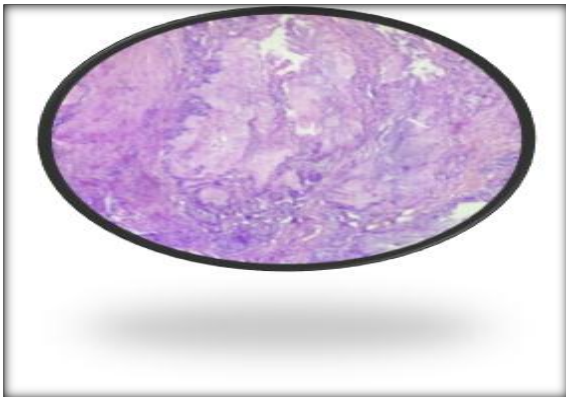


Figure 1: Showing collections of amorphous amphiphilic material Gouty tophi. (x100, H &E)

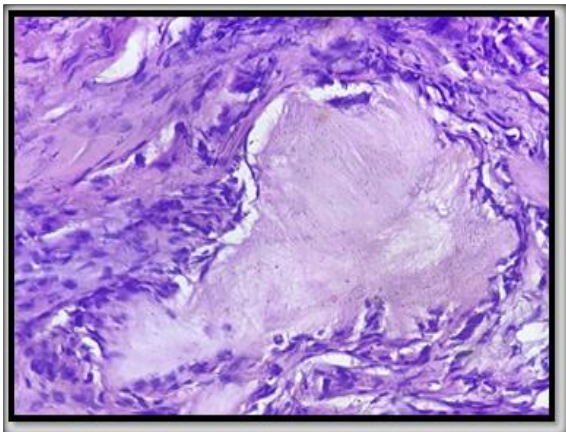


Figure 2: showing Gouty tophus rimmed by histiocytes and multinucleated foreign body type of giant cells (x400, H&E)



Figure 3: Gross: Synovectomy specimen from Knee joint in a case of Primary synovial chondromatosis showing Hyaline cartilaginous nodules within the synovium and free within joint spaces

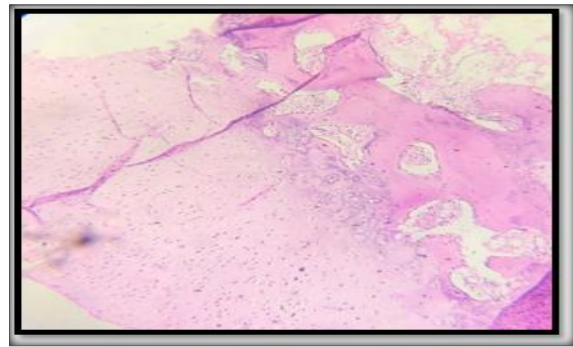


Figure 4: Osteochondral loose bodies with clustering of chondrocytes and adjacent areas with enchondral ossification (H & E X100)

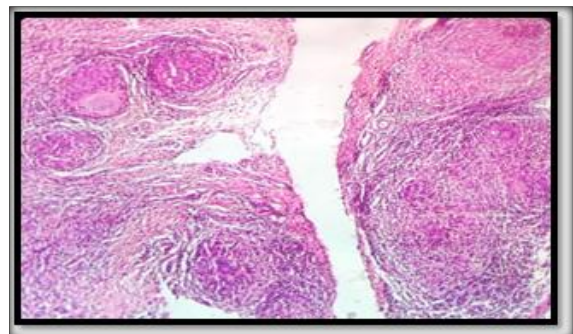


Figure 5: Synovial bx from wrist joint showing granulomas composed of epithelioid cells, Langhans type of giant cells and lymphocytes in a case of Tuberculous synovitis

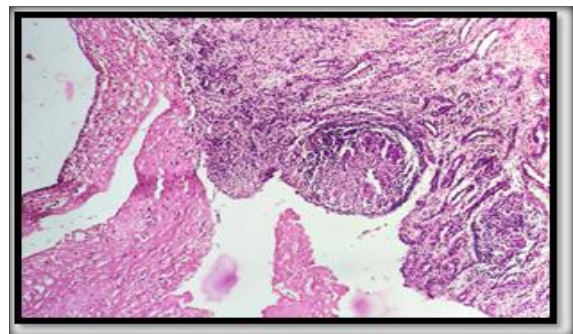


Figure 6: Rheumatoid arthritis-Synovial tissue with dense inflammation and surface fibrinoid necrosis (H & E x40)

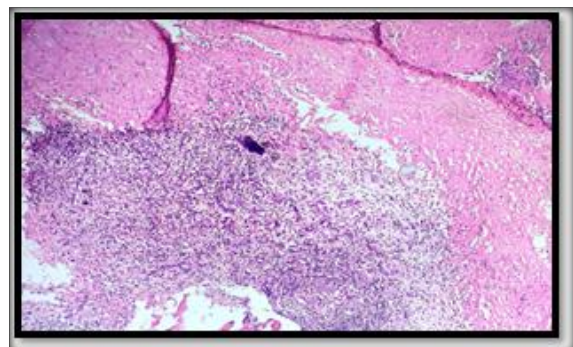


Figure 7: Rheumatoid arthritis-increased vascularity, lymphoplasmacytic infiltrate, fibrinoid necrosis (H & E x100)

Table 1: Age group wise distribution (N=100)

Age group (Years)	No.
11-30	17
31-50	13
51-70	38
71-90	32
Total	100

Table 2: Distribution of various synovial lesions according to etiology and gender

S.No.	Lesion	Male	Female	Total
1	Inflammatory Joint Diseases			
a	Infections			
	• Septic arthritis	4	6	10
	• Tuberculous synovitis	4	2	6
b	Autoimmune			
	• RA	1	5	6
c	Others			
	• Chronic nonspecific synovitis	4	14	18
2	Degenerative Joint Diseases			
a	OA	4	6	10
b	Gout	2	1	3
c	Pseudogout	1	2	3
d	Oochronosis	2	-	2
e	Avascular necrosis	3	2	5
3	Tumor and tumor like lesions			
a	Synovial chondromatosis	2	6	8
b	GCT of tendon sheath	8	7	15
c	PVNS	2	2	4
d	Synovial lipoma arborescence	3	7	10
Total		40	60	100

DISCUSSION

The increasing life expectancy, rising prevalence of obesity, and sedentary lifestyles have contributed to a significant rise in the incidence and prevalence of joint disorders, particularly arthritis. The present study aimed to explore the histopathological spectrum of synovial biopsies, providing critical insights into the underlying pathology of various arthritides, neoplastic conditions, and infections affecting the synovium.

Age and Gender Distribution: The study found that the most commonly affected age groups were the 6th and 7th decades of life. This finding aligns with previous studies by Singhal et al.^[7] (2012) and Vordenbäumen et al.^[8] (2009), which reported similar age distributions for synovial pathologies. However, studies by Mussawy et al.^[9] (2022) noted a higher incidence of inflammatory joint disorders in younger age groups (2nd and 3rd decades), indicating a possible variation in the population demographics attending orthopedic outpatient departments.

Females were more frequently affected than males, with a male-to-female ratio of 1:1.5. This gender distribution contrasts with studies by Sharma et al.^[11] (2020) and Vordenbäumen et al.^[8] (2009), which reported a higher prevalence of synovial lesions in males. However, the higher incidence of rheumatoid arthritis among females in our study is consistent with the autoimmune nature of the disease, which is known to predominantly affect women (Scott et al.^[12] 2010).

Inflammatory Joint Diseases: Chronic nonspecific synovitis was the most common inflammatory condition, accounting for 18% of cases. This finding is in line with the study by Singhal et al.^[7] (2012), highlighting the prevalence of chronic nonspecific inflammation in synovial biopsies. Septic arthritis and tuberculous synovitis were also notable, with higher incidences in females for septic arthritis and males for tuberculous synovitis. The prevalence of tuberculous synovitis (6%) is consistent with findings by Sharma et al.^[7] (2020), Vordenbäumen et al.^[8] (2009), and Mussawy et al.^[9] (2022).

Degenerative Joint Diseases: Osteoarthritis was observed in 10% of cases, predominantly affecting females. This prevalence is lower than the 45.6% reported by Mussawy et al.^[9] (2022), likely due to the latter study's focus on a knee replacement center. Gout and pseudogout cases were relatively rare, with ochronosis observed exclusively in males, presenting characteristic clinical features such as darkened urine upon exposure to air, hip, and knee pains, consistent with findings by Siavashi et al.^[10] (2009).

Tumor and Tumor-like Lesions: Giant Cell Tumor (GCT) of the tendon sheath was the most prevalent lesion within the tumor group, accounting for 15% of cases. This contrasts with the fewer cases reported in studies by Singhal et al.^[7] (2012), Vordenbäumen et al.^[8] (2009), and Mussawy et al.^[9] (2022). Synovial chondromatosis, a rare condition characterized by ectopic cartilage formation, was observed in 8% of cases, higher than reported in other studies. Pigmented Villonodular Synovitis (PVNS) and synovial lipoma arborescence were also

noted, with the latter showing a higher prevalence in our study compared to others.

Our findings highlight the diverse histopathological spectrum of synovial lesions, with significant variations in age, gender, and specific conditions compared to other studies. These differences underscore the importance of localized data in understanding the epidemiology of synovial pathologies and tailoring diagnostic and therapeutic approaches accordingly.^[13,14]

Clinical Implications: Histopathological examination of synovial biopsies remains a valuable diagnostic tool, particularly in early and ambiguous cases of joint diseases. The identification of specific inflammatory, degenerative, and neoplastic conditions through biopsy can guide appropriate treatment strategies, improving patient outcomes. Our study emphasizes the necessity for comprehensive histopathological evaluation in managing joint diseases, particularly in settings with diverse patient populations.

Limitations: The study's cross-sectional design limits the ability to assess longitudinal changes in synovial pathology. Additionally, the exclusion of samples with inadequate material may introduce selection bias. Future studies with larger sample sizes and longitudinal follow-ups are warranted to further validate and expand upon these findings.

CONCLUSION

The study underscores the diagnostic value of synovial biopsies in elucidating the histopathological landscape of joint diseases. The findings reveal a higher prevalence of inflammatory and degenerative conditions, with notable gender and age-related variations. These insights contribute to the existing knowledge and highlight the need for targeted diagnostic and therapeutic approaches in managing synovial pathologies.

REFERENCES

1. Mapp PI, Walsh DA. Mechanisms and targets of angiogenesis and nerve growth in osteoarthritis. *Nat Rev Rheumatol*. 2012 May 29;8(7):390-8. doi: 10.1038/nrrheum.2012.80. PMID: 22641138.
2. Chauhan K, Jandu JS, Brent LH, et al. Rheumatoid Arthritis. [Updated 2023 May 25]. In: StatPearls [Internet]. Treasure Island (FL): StatPearls Publishing; 2024 Jan-. Available from: <https://www.ncbi.nlm.nih.gov/books/NBK441999/>

3. Haringman JJ, Gerlag DM, Zwinderman AH, Smeets TJ, Kraan MC, Baeten D, McInnes IB, Bresnihan B, Tak PP. Synovial tissue macrophages: a sensitive biomarker for response to treatment in patients with rheumatoid arthritis. *Ann Rheum Dis*. 2005 Jun;64(6):834-8. doi: 10.1136/ard.2004.029751. Epub 2004 Dec 2. PMID: 15576415; PMCID: PMC1755544.
4. Bresnihan B. Are synovial biopsies of diagnostic value? *Arthritis Res Ther*. 2003;5(6):271-8. doi: 10.1186/ar1003. Epub 2003 Oct 2. PMID: 14680502; PMCID: PMC333414.
5. Ingegnoli F, Coletto LA, Scotti I, Compagnoni R, Randelli PS, Caporali R. The Crucial Questions on Synovial Biopsy: When, Why, Who, What, Where, and How? *Front Med (Lausanne)*. 2021 Aug 6; 8:705382. doi: 10.3389/fmed.2021.705382. PMID: 34422862; PMCID: PMC8377390.
6. Obeidat AM, Kim SY, Burt KG, Hu B, Li J, Ishihara S, Xiao R, Miller RE, Little C, Malfait AM, Scanzello CR. Recommendations for a Standardized Approach to Histopathologic Evaluation of Synovial Membrane in Murine Models of Experimental Osteoarthritis. *bioRxiv [Preprint]*. 2023 Oct 18:2023.10.14.562259. doi: 10.1101/2023.10.14.562259. PMID: 37904981; PMCID: PMC10614774.
7. Singhal O, Kaur V, Kalhan S, Singhal MK, Gupta A, Machave Y. Arthroscopic synovial biopsy in definitive diagnosis of joint diseases: An evaluation of efficacy and precision. *Int J Appl Basic Med Res*. 2012 Jul;2(2):102-6. doi: 10.4103/2229-516X.106351. PMID: 23776821; PMCID: 20091166.
8. Vordenbäumen S, Joosten LA, Friemann J, Schneider M, Ostendorf B. Utility of synovial biopsy. *Arthritis Res Ther*. 2009;11(6):256. doi: 10.1186/ar2847. Epub 2009 Nov 23. PMID: 19951395; PMCID: PMC3003519.
9. Mussawy H, Zustin J, Luebke AM, Strahl A, Krenn V, Rütther W, et al. The histopathological synovitis score is influenced by biopsy location in patients with knee osteoarthritis. *Arch Orthop Trauma Surg*. 2022 Nov;142(11):2991-2997. doi: 10.1007/s00402-021-03889-x. Epub 2021 Apr 10. PMID: 33837812; PMCID: PMC9522683.
10. Siavashi B, Zehtab MJ, Pendar E. Ochronosis of hip joint; a case report. *Cases J*. 2009 Dec 16; 2:9337. doi: 10.1186/1757-1626-2-9337. PMID: 20062596; PMCID: PMC2803996.
11. Sharma P, Gupta R, Bhardwaj S, Mahajan M. Cytomorphological Evaluation of Synovial Lesions in a Tertiary Care Centre in North India: A Retrospective Study. *J Cytol*. 2020 Oct-Dec;37(4):166-169. doi: 10.4103/JOC.JOC_66_20. Epub 2020 Nov 6. PMID: 33776255; PMCID: PMC7984514.
12. Scott DL, Wolfe F, Huizinga TW. Rheumatoid arthritis. *Lancet*. 2010 Sep 25;376(9746):1094-108. doi: 10.1016/S0140-6736(10)60826-4. PMID: 20870100.
13. Efridi W, Dhmoon AS. Ochronosis. [Updated 2023 Aug 8]. In: StatPearls [Internet]. Treasure Island (FL): StatPearls Publishing; 2024 Jan-. Available from: <https://www.ncbi.nlm.nih.gov/books/NBK560534/>
14. Smits M, van de Groes S, Thurlings RM. Synovial Tissue Biopsy Collection by Rheumatologists: Ready for Clinical Implementation? *Front Med (Lausanne)*. 2019 Jun 20; 6:138. doi: 10.3389/fmed.2019.00138. PMID: 31281817; PMCID: PMC6595539.